

SAMPLE ULTRASOUND REPORT TO LMC

(if different reports are sent to the Laboratory and the LMC)

Hospital No:	
Exam Date:	9 August 2010

Dear

Thank you for referring your patient

INDICATION:	Nuchal translucency scan. For first trimester combined screening.		
History:			
Maternal age:	31 years		
Last period:	15 May 2010		

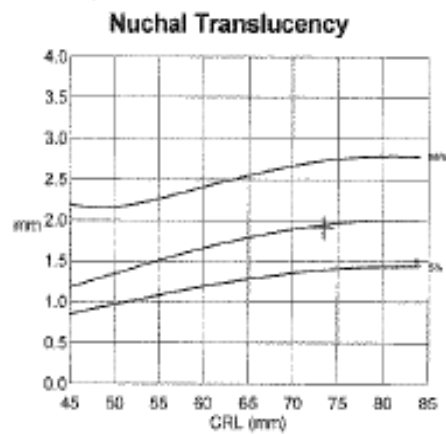
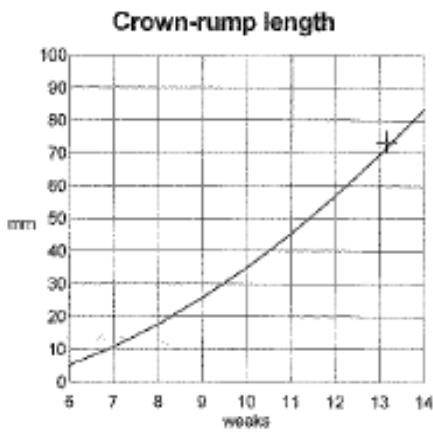
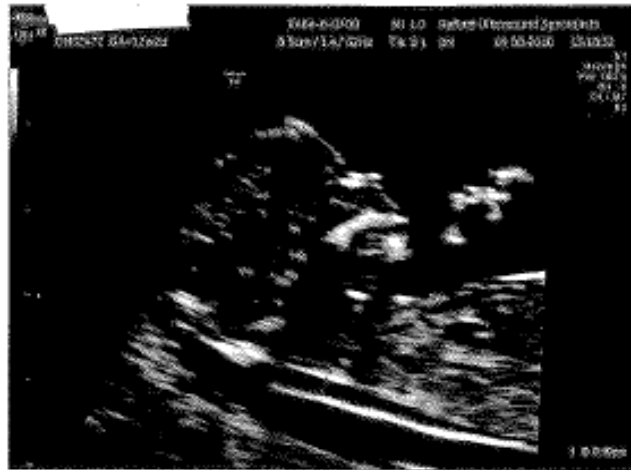EDD by ultrasound:	13 February 2011	EDD by dates:	19 February 2010
Gestational age:	13 weeks + 1 day	Gestational age by dates	12 W+ 2 D*

First Trimester Ultrasound:			
Transabdominal US with Voluson E8	Ultrasound view:	Good	
Fetal heart action present	Frequency	150	bpm
Crown-rump length (CRL)		73.4	mm
Biparietal diameter (BPD)		23.5	mm
Nuchal translucency (NT)		1.90	mm
Nasal bone (tick one or leave blank)			
	✓	Not looked for	
		Present	
		Absent	
		Not able to be visualised for technical reasons	

Fetal anatomy:	
Skull/brain appears normal, heart not examined, spine appears normal, abdomen appears normal, stomach visible, bladder visible, hands both visible, feet both visible.	
Placenta:	Anterior
Amniotic fluid:	Normal

Maternal Structures:	
Right ovary:	normal morphology
Left ovary:	normal morphology

Summary:	
Normal first trimester scan. NT=1.9 mm. First trimester combined screening is planned, therefore risk assessment has not been performed. 13 weeks 1 day +/- 7 days by scan today.	



Name of Specialist:	
Sonographer Initials:	