

SAMPLE FIRST TRIMESTER TWIN ULTRASOUND REPORT

Exam Date:	
Referrer (name and address)	

Patient:	
DOB:	
NHI:	

INDICATION:	Nuchal translucency scan. For combined screening.
History:	
Maternal age:	34 years

EDD by ultrasound:	19 July 2011
Gestational age:	12 weeks + 1 day

First Trimester Ultrasound:			
Transabdominal US with Voluson E8 Live twin pregnancy, monochorionic, diamniotic	Ultrasound view:	Good	

Twin 1 (left):			
Fetal heart action present	Frequency	156	bpm
Crown-rump length (CRL)		55.1	mm
Biparietal diameter (BPD)		19.4	mm
Nuchal translucency (NT)		1.40	mm
Nasal bone (tick one or leave blank)		Not looked for	
	✓	Present	
		Absent	
		Not able to be visualised for technical reasons	

Fetal anatomy:	
Skull/brain appears normal, heart not examined, spine appears normal, abdomen appears normal, stomach visible, bladder visible, hands both visible, feet both visible.	
Placenta:	Posterior
Amniotic fluid:	Normal

Twin 2 (right):			
Fetal heart action present	Frequency		bpm
Crown-rump length (CRL)			mm
Biparietal diameter (BPD)			mm
Nuchal translucency (NT)			mm
Nasal bone (tick one or leave blank)		Not looked for	
	✓	Present	
		Absent	
		Not able to be visualised for technical reasons	

Fetal anatomy:

Skull/brain appears normal. **Heart** not examined, **spine** appears normal, **abdomen** appears normal, **stomach** visible, **bladder** visible, **hands** both visible, **feet** both visible.

Placenta: Posterior

Amniotic fluid: Normal

Maternal Structures:

Right ovary: normal morphology

Left ovary: normal physiologic change, contains a haemorrhagic corpus luteum

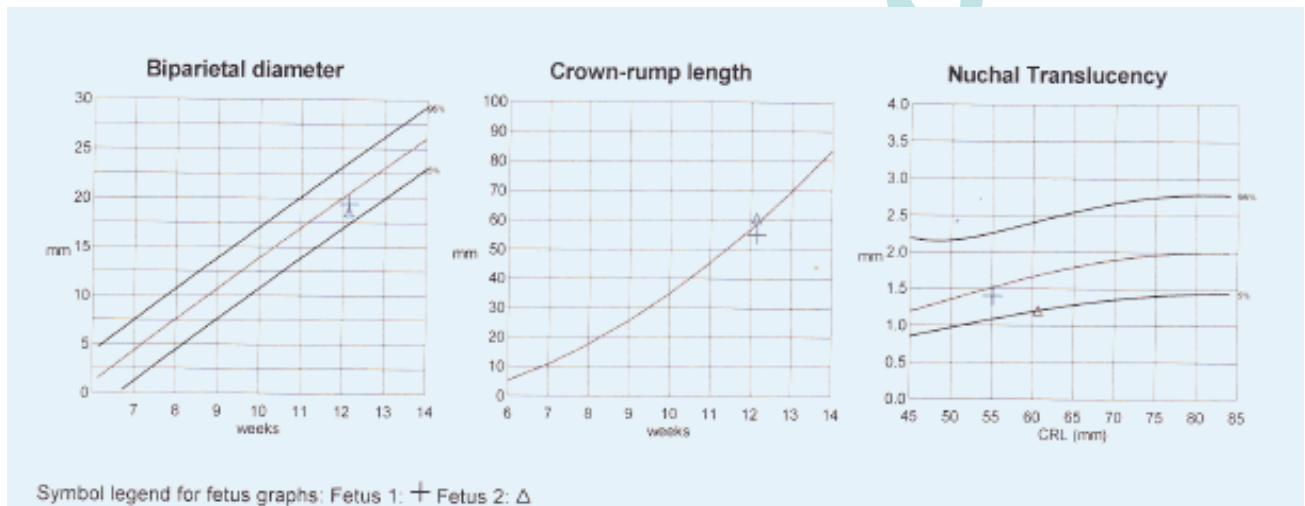
Summary:

Monochorionic, diamniotic twin pregnancy.

Twin 1 (left): Normal first trimester scan. NT=1.4mm.

Twin 2 (right): Normal first trimester scan. NT=1.2mm.

Combined screening is planned, therefore risk assessment has not been performed.



Name of Specialist:

Sonographer Initials: